

RESEARCH ARTICLE

Transcatheter balloon valvuloplasty for children with severe pulmonary valve stenosis: A single-center experience

Munaf Jarallah Yaseen¹, Sura Abd Alwahab¹, Nabeeha Najatee Akram^{2*}, Wassan Nori³

1. Department of Pediatrics, College of Medicine, Baghdad University, Baghdad, Iraq

2. Department of Pediatrics, College of medicine, Mustansiriyah university, Baghdad, Iraq

3. Department of Obstetrics and Gynecology, College of medicine, Mustansiriyah university, Baghdad, Iraq

Objectives: this study aim to assess the effectiveness of the Transcatheter balloon valvoplasty (BVP) of severe Pulmonary stenosis (PS) and identify possible complications and predictors for the outcome.

Methods: A retrospective study was conducted at the Iraqi Center of Cardiac Diseases for a 2-year duration in the period from 2021 to the end of 2023; the patients with confirmed severe PS of both genders within the age equal to or less than 18 years were included. For every patient included in the present study, the following data were collected: Demographic data, Echocardiographic criteria Hemodynamic parameters pre- and post-Cath, Catheterization data including the site of vascular access, need for general anesthesia and tracheal intubation, number and size of balloons used, any complications recorded at therapeutic session obtained from Cath lab archive.

Results: After BVP, the pressure gradient across the valve reduced from 105 ± 25 to 32 ± 11 (mmHg), ($P < 0.001$); the systemic right ventricular pressure dropped from 120 ± 25 (mmHg) before to 54 ± 14 (mmHg) after ($P < 0.001$). A significant increase in the systemic pulmonary pressure from 18 ± 4 (mmHg) before to 22 ± 3 (mmHg) ($P < 0.001$). Tricuspid valve regurgitation (TVR) reduced significantly ($P = 0.002$). Pulmonary incompetence (PI) changed from mild to moderate and severe in 12 cases ($P = 0.001$). Nine cases (20%) developed complications; 6 (13.3%) supraventricular tachycardia and 3 (6.7%) Cardiac arrest and cardiopulmonary resuscitation. The strongest association to complication occurrence was pulmonary valve annulus size with $r = 0.417$ and TVR and PI severity with $P = 0.001$, 0.017 , respectively.

Conclusion: Transcatheter BVP is an effective procedure for severe PS cases but carry a risk of cardiac complications. The complication rate was linked to the patients' demographical characteristics and PV annulus size and degree of TVR and PI severity.

Keywords: congenital heart disease, severe pulmonary stenosis, tricuspid stenosis

Received 7 December 2024 / Accepted 3 January 2025

Introduction

Pulmonary stenosis (PS) is a cyanotic congenital heart disease that constitute 8–10 % of all heart defects at birth and is usually present in conjugation with other types of congenital anomalies of the heart [1]. However, Isolated PS is a rare condition that occurs in about 1 per 2000 live births worldwide, with higher prevalence reported in Asia [2,3].

The obstruction of the right ventricular out flow tract had different forms includes valvular, supra-valvular, or sub-valvular depending on the site of obstruction, PS severity divided into mild, moderate, or severe depending on the degree of obstructions [4] which is usually made by measuring the pressure gradient (PG) across the pulmonary valve or the ratio of right ventricular peak systolic pressure to left ventricular peak systolic pressure. Severe PS is defined as a peak gradient more significant than 64 mm Hg across the valve [2] or being present when the right ventricular systolic pressure (RVP) equals or exceeds the left ventricular systolic pressure [5] According to Echo, severe PS is suggested when blood flow velocity across the pulmonary valve (PV) is equal to or more than four m/sec [6] Although patients with mild PS tend to be asymptomatic

with an incidental finding of a murmur, those with severe PS usually present with chest pain, dyspnea, and even right sided heart failure [7].

The recent guidelines recommend that patients with severe valvular stenosis with less than moderate pulmonic valve regurgitation should be managed initially by transcatheter balloon valvuloplasty while surgical repair is ideal when patients are ineligible or after the failure of balloon valvuloplasty [8,9].

The transcatheter balloon valvuloplasty is suitable only for those with valvular PS, while dysplastic valves, infundibular stenosis, presence of hypoplastic annulus, or other associated cardiac lesions represent an indication for surgical repair [10,11]. Multiple studies demonstrate the effectiveness of the procedure and short-term follow-up in specific groups, but few papers report medium- and long-term follow-ups, and that include the different groups of patients with pulmonary valve stenosis (neonates, critical stenosis or associated with other congenital heart diseases [12]. This study evaluated the efficacy and outcomes of transcatheter balloon valvuloplasty for severe pulmonary stenosis in a single cardiac center, while also analyzing the associated complications and identifying factors significantly correlated with their occurrence.

* Correspondence to: Nabeeha Najatee Akram
E-mail: nabaha@uomustansiriyah.edu.iq

Methods

Study design and setting

A retrospective study was conducted at the Iraqi Center of Cardiac Diseases for a 2-year duration in the period from the 1st of October 2021 to the 30th of September 2023. Patients were recruited in the study when they matched the following inclusion criteria:

1. Age of patients equals to or less than 18 years;
2. Transcatheter balloon valvoplasty done for severe PS, which was diagnosed by Echo (blood flow velocity across pulmonary valve PV equal to or more than four m/sec or PG more than 64 mmHg).

Patients with any of the following exclusion criteria were excluded from the study:

3. age more than 18 years;
4. PS is a part of other congenital heart diseases or with other levels of right ventricular outflow tract obstruction;
5. dysplastic pulmonary valve;
6. missing data or lost follow-up.

Variables Measured in the Study

For every patient included in the present study, the following data were collected:

- Demographic data, including patient's age, gender, and weight
- Echocardiographic criteria (blood flow velocity across PV, right-sided dilatation, tricuspid valve incompetence, doming of pulmonary valve, right ventricular function, the pressure gradient across PV, PV annulus size, and any other associated lesions).
- Hemodynamic parameters pre- and post-Cath (SRV pressure (mmHg), SPA pressure (mmHg), PG (mmHg), severity of Tricuspid regurgitation (TR), Pulmonary incompetence (PI)s.
- Catheterization data: site of vascular access, need for general anesthesia and tracheal intubation, number and size of balloons used, any complications recorded at therapeutic session obtained from cath lab archive.
- The size of the balloon, the size of the annulus, the ratio of balloon to annulus size

- Complications and fate of patients during the procedure or on follow-up.

Transcatheter balloon valvoplasty details

All recruited cases were patients in the same cardiac center and managed by the same pediatric cardiologist to overcome the effects of years of experience with different cardiologists.

The Traditional balloon valvoplasty was done for most of the cases in the following steps: After having vascular access by femoral approach, an appropriate-size multipurpose catheter was introduced to the right ventricle, right ventriculogram in full lateral projection obtained to explore the PV anatomy and measure the PV annulus angiographically. Pressure gradient (PG) across stenotic PV is measured by subtraction of systolic pulmonary artery pressure (PA PR) from that of RV. Transcatheter balloon with a size 1.2-1.4 times that of the annulus size sliding over an extra stiff guide wire for inflation of the stenosed PV annulus. In all cases, Traditional balloon valvoplasty was used, but in two cases, a *Kissing balloon technique* was used. Because the size of the pulmonary annulus was large and no suitable balloons were available to minimize the femoral vein trauma, bilateral vascular accesses were obtained, and two different assistants introduced two balloons to the heart. The two balloons, when at the pulmonary annulus, inflated simultaneously, as seen in Figure 1.

The following types of balloons were used: Tyshak (NuMED, USA), Osypka VACS II (Osypka, Germany), Valver (Balton, Poland), and Z-MED™ (Numed, USA). The type of balloon was selected according to availability, and for each period, one type of balloon was available at the center. The procedure is considered successful if residual PG across PV is less than 35mmhg. The pulmonary and tricuspid regurgitation following the procedure were graded as mild, moderate, and severe [13].

Statistical analysis

Data were managed, processed, and analyzed using the statistical package for Social Sciences version 28 (SPSS 28). Descriptive statistics are presented as mean, standard devi-

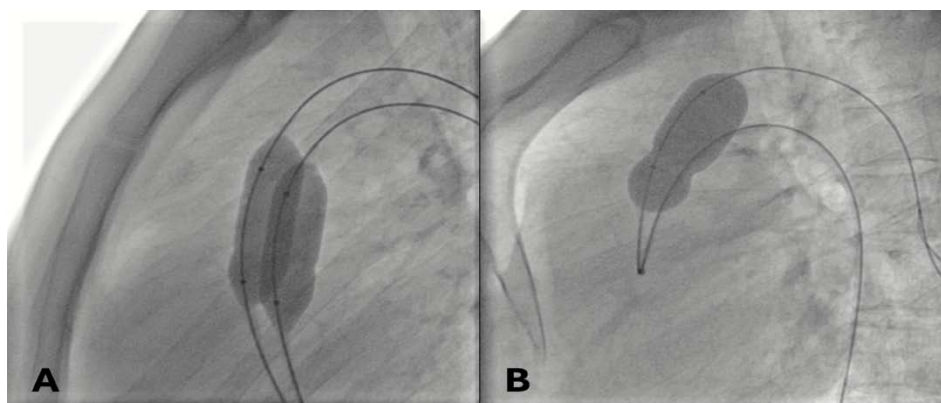


Fig. 1. Lateral angiograms demonstrate an inflated balloons across the pulmonary valve. A: Kissing balloon technique, B: Traditional balloon valvoplasty.

ation, median, interquartile range (IQR), frequency (No.), and simple percentage (%) according to the type of variables. Parameters mean values before and after balloon valvoplasty were compared using paired t-test. Frequencies of severity were compared using Chi-square and Fisher's exact tests when applicable. Univariate and bivariate correlation analysis was performed to assess the correlation between incident complications and other variables. All statistical tests were performed at a level of significance (P value) of ≤ 0.05 to be significant.

Ethical approval

The ethical committee at Baghdad university-college of medicine approved the study with approval number (41) dated on 23-4-2024.

Results

In A total of 45 patients matched the inclusion criteria and were included in the analysis. Patients' ages ranged between 4 months and 18 years, with an interquartile range (IQR) of 1 – 8.5 years. 20.0% of them were < 1 year old, 46.7% were 1-5 years of age, and 33.3% were > five years old. The patients' weight ranged from (9-24) Kg with an IQR of 14.

Females outnumbered males with 53.3% vs. 46.7% respectively. None of the patients had syndromic features. Before balloon valvoplasty, most cases had no RV dysfunction (80%) compared to those with dysfunction 20%. The most frequent access site was the femoral vein, followed by the femoral artery (93.3% vs. 8.9%) respectively. General anesthesia was used in most cases while general anesthesia with tracheal intubation (88.9 % vs. 26.7%) respec-

tively. Osypka was the predominant type of balloon used (64.4%), followed by Tyshak in 20%. Most patients required only one balloon per session (73.3%), and 26.7% needed two balloons. The double-balloon (Kissing balloon technique) was used in only 4% of the cases. The mean PV annulus was 11.67 ± 3.087 , while the mean balloon size used was 15.96 ± 3.69 . The mean value for the balloon /PV annulus ratio was 1.38 ± 0.08 . The complication occurred in 9 (20) % of the cases, distributed as SVT and, cardiac arrest and CPR, with incidents of 13% vs 7%, respectively as seen in Table 1.

Regarding changes in SRV pressure, SPA pressure, and PG after balloon valvoplasty, a significant reduction was reported in SRV pressure from 120 ± 25 (mmHg) before to 54 ± 14 (mmHg) after ($P < 0.001$). A significant increase in the SPA pressure was reported after balloon valvoplasty, from 18 ± 4 (mmHg) before to 22 ± 3 (mmHg) after ($P < 0.001$). As for PG, it reduced from 105 ± 25 (mmHg) before to 32 ± 11 (mmHg) after ($P < 0.001$), as shown in Figure 2.

A comparison of the severity of tricuspid regurgitation (TR) and pulmonary incompetence (PI) before and after balloon valvoplasty revealed a significant change in the severity of both, as highlighted in Figure 3. The severity of TR reduced significantly ($P = 0.002$). Severe TR found in (28.9%) to zero after intervention. Moderate cases dropped from 14 (31.1%) to 13 (28.9%), and mild cases increased from 18 (40%) to 32 (71.1%) after intervention. The PI severity changed significantly ($P = 0.001$) out of 45 (100%) mild PI before balloon valvoplasty into 33 (37.3) after. Moderate and severe PI was shown after the intervention in 12 cases.

Table 1. The catheterization and balloon-related variables

Variable		Total (45) No. (%)
RV dysfunction before the Cath	Yes	9(20%)
	No	36(80%)
Venous access used during catheterization	Femoral	42 (93.3%)
	Subclavian	3(6.7%)
Artery access used during catheterization	Yes	4(8.9%)
	No	41(91.1%)
General anesthesia use during catheterization.	Yes	40(88.9%)
	No	5(11.1%)
Endotracheal tube during catheterization	Yes	12(26.7%)
	No	33(73.3%)
Type of balloon used	Osypka	29(64.4%)
	Tyshak	10(22.2%)
	Balloon	5(11.1%)
	Z-MED™	1(2.2%)
Number of balloons used per session	One	33(73.3%)
	Two	12(26.7%)
Double balloon tech (kissing balloon)	Yes	2(4.4%)
	No	43(95.6%)
PV annulus size (mm)		$11.67 \pm 3.087^{**}$
Balloon size (mm)	Data expressed as mean \pm SD	$15.96 \pm 3.69^{**}$
Balloon/PV annulus ratio		$1.38 \pm 0.08^{**}$
Incidence of complication	Yes	80%
	No	20%
Type of complication	SVT	6(13.3%)
	Cardiac arrest & CPR	3(6.7%)

** analysis done by student t-test. RV: right ventricle, PV: pulmonary valve, SVT: supraventricular tachycardia, CPR: cardiopulmonary resuscitation

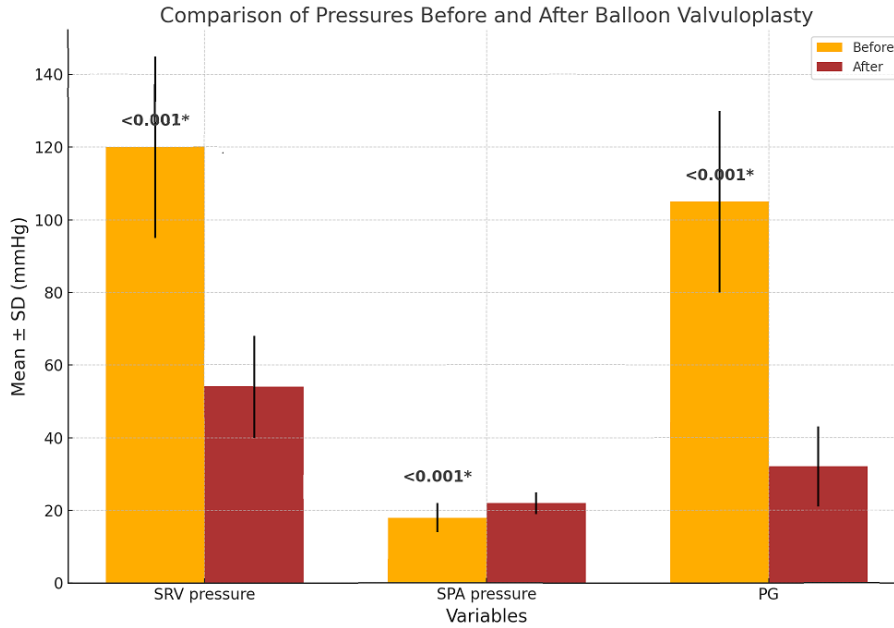


Fig 2. Comparison of SRV pressure, SPA pressure, and PG before and after balloon valvuloplasty of the studied group (N=45). SRV: Systemic right ventricular, SPA: Systemic pulmonary artery, PG: Pulmonary Gradient. *High significant difference at P<0.05.

The bivariate correlation analysis shows that seven parameters were significantly linked to the incidence of complications in balloon valvuloplasty. These are age, body weight, ET during catheterization, PV annulus size (which showed moderate correlation compared to others that had weak correlations), balloon size, P<0.05. see Table 2. In comparison, the gender did not show a significant correlation with incident of complication P value > 0.05 (not shown in table).

Cross-tabulation for the frequency of complications with respect to TR and PI severity after balloon valvuloplasty showed that complications occurred in 20% of the cases compared to 80% who did not suffer any complications. The complication rate was significantly associated

with the severity of TR and PI post after balloon valvuloplasty, and the difference was statistically significant (0.001 and 0.017), respectively, Table 3.

Further analysis was performed using binary regression testing using the complications as the dependent variable against age, sex, weight, ET during catheterization, PV annulus size, balloon size, TR severity, and PI severity after balloon valvuloplasty as an independent variable. This analysis showed that all of these variables except sex were significant predictors of complications with an Odds ratio OR ranging between 1.25 to 1.84 in all these variables P value <0.05). Sex appeared as a non-significant predictor (P value = 0.881), as shown in Table 4.

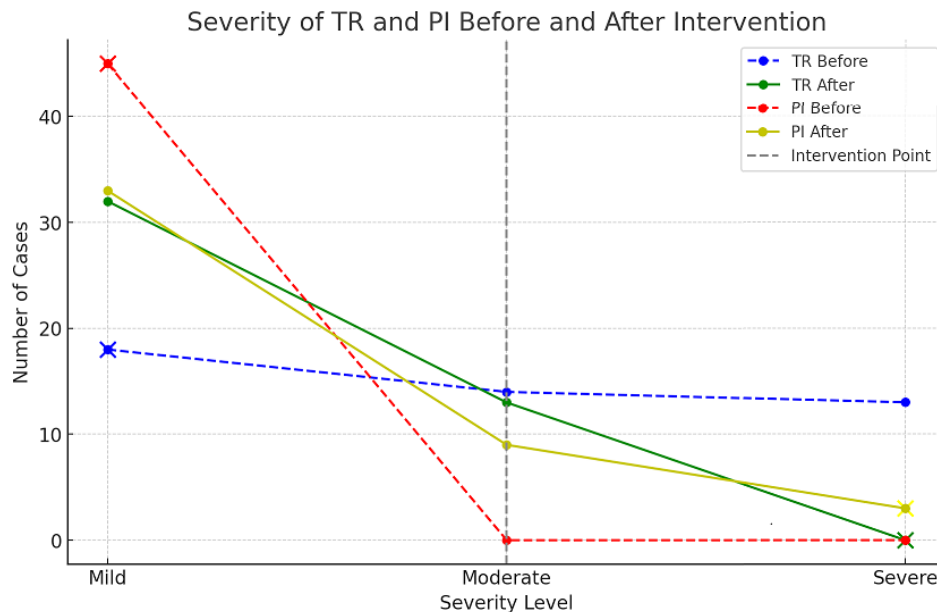


Fig 3: Comparison of the severity of TR and PI before and after balloon valvuloplasty in the studied group (N=45). TR: tricuspid regurgitation, PI: pu1lmonary incompetence.

Table 2: Pearson correlation between demographic criteria versus complications in balloon valvoplasty

Variable	Correlation coefficient	P-value
Age	0.396	0.007
Weight (kg)	0.374	0.011
ET during catheterization	0.359	0.015
PV annulus size (mm)	0.417	0.004
Balloon size (mm)	0.387	0.009

ET: endotracheal intubation, PV: pulmonary valve

Table 3. Correlation between complications incidence after TBV based on TR and PI severity

Parameter		No complication No. (%)	With complication No. (%)	Total	P-value*
TR severity after balloon	Mild	29(90.6%)	3(9.4%)	32	0.001
	Moderate	7(53.8%)	6(46.2%)	13	
PI severity after balloon	Mild	31(93.9%)	2(6.1%)	33	0.017
	Moderate	4(44.4%)	5(55.5%)	9	
	Severe	1(33.3%)	2(66.6%)	3	
Total		36(80%)	9(20%)	45	

TR: tricuspid regurgitation, PI: pulmonary incompetence

Table 4. Results of binary regression analysis for the predictors of post-balloon valvuloplasty complications

Variable in the equation	B	S.E.	OR	95% C.I. for OR	P-value
Age	0.46	0.16	1.59	1.28 – 1.90	0.005
Sex	0.04	0.11	1.04	0.82 – 1.26	0.881
Weight	0.38	0.14	1.46	1.19 – 1.74	0.009
ET during catheterization	0.22	0.10	1.25	1.06 – 1.44	0.028
PV anulus size	0.45	0.14	1.56	1.30 – 1.83	0.003
Balloon size	0.39	0.12	1.47	1.24 – 1.70	0.007
TR severity after balloon valvuloplasty	0.44	0.13	1.55	1.30 – 1.80	0.005
PI severity after balloon valvuloplasty	0.61	0.19	1.84	1.48 – 2.21	0.001

ET: endotracheal intubation, PI: pulmonary incompetence, PV: pulmonary valve TR: tricuspid regurgitation.

Discussions

Although transcatheter balloon valvoplasty has been assigned as the treatment of choice for pediatric patients with severe valvular PS since 1982 [14], data in developing countries, including Iraq, is sparse about the efficacy of such a procedure. This is the first Iraqi study that describes the outcome of transcatheter balloon valvoplasty in pediatric population with severe PS.

Most patients with severe valvular pulmonary stenosis nowadays are managed during childhood [15]. In the current study, the median age of patients who underwent transcatheter balloon valvuloplasty was three years; this matches studies by Parezanovic et al. [16] and Voet et al. [17]. General anesthesia during the procedure is preferred in pediatric patients [18] and this matches the findings in the present study as the majority of children, 88.9%, needed general anesthesia during the procedure. However, only 26.7% needed endotracheal intubation, and the rest of the patient laryngeal tube was used.

The analysis showed a significant reduction in each of SRV pressure, SPA pressure, and PG after balloon angioplasty ($P < 0.001$), which agrees with that found by Manal et al. study, which carried in infants with immediate improvement of the condition [19]. Moreover, it agrees with Karagoz T et al. and Weryński et al. [20,21]. Rao PS. The results of several investigators who documented impressive results of BPV in children were reviewed, and all data reported immediate significant improvement of pulmonary valve pressure gradient in neonates, children, and adults

[22]. An adolescent study in Pakistan also declared the procedure as very safe procedure with high success [23]. In addition, EL-saeidi et al identified predictors for success including the absence of infundibular and supravalvular stenosis and a large pulmonary valve diameter [24].

The present study showed that TR severity reduced significantly ($P = 0.002$). The evidence presented is in line with the data from other studies, such as Fawzy M et al., which demonstrated that severe TR in about seven patients either improved or entirely resolved during the follow-up period following valvoplasty [25]. Similarly, Mechmeche R et al. observed that patients with significant pulmonary stenosis and right ventricular failure experienced complete remission of tricuspid insufficiency within five years following balloon pulmonary valvuloplasty [26]. Similarly, Weber H. exhibited the reversion of tricuspid valve inadequacy and the eradication of right-to-left shunting at the atrial level in a comparable group of patients [27].

In transcatheter balloon valvoplasty, a severe PS represents a risk factor for more than moderate pulmonary regurgitation following valvoplasty [28], this match results in this study as pulmonary incompetence (PI) changed from mild to moderate and severe in 12 cases ($P = 0.001$). Parezanovic et al. reported that pulmonary valve insufficiency after dilatation occurred in 6.6% of cases and was most common in children aged up to 12 months [16]. On the other hand, in Mughal et al post procedure echocardiography did not detect any case of moderate or severe pulmonary valve regurgitation (PR) while mild PR was

observed in about half of the patients, and this could be attributed to older age group in their study than the current study [23].

The degree of pulmonary and tricuspid regurgitation following valvoplasty did not correlate with patients' age, gender, and body weight, and this does not match the results by Yin et al., who identified several risk factors for pulmonary regurgitation that occur post valvoplasty for pulmonary stenosis include the young age of patients, low weight at the time of the procedure, and small annulus diameter [28]. This difference could be attributed to differences in characteristics between samples in addition to differences in the procedures used, such as Yin et al.'s use of a single balloon in all patients. In contrast, in the present study, in 12 patients (26.7%), two balloons were used during the procedure, and 2 cases needed kissing balloon valvoplasty, and the two balloon methods are known to increase the risk of pulmonary regurgitating [29]. The type of the balloon used in the current study was mainly dependent on the availability, as at each period a single balloon type available at the center. This resulted in using Osypka in (64.4%) of patient which is made from non-compliant material with high durability and suitability for high pressures [30]. Establishment of the effect of the type of the balloon used in comparison with previous studies where not feasible as previous studies did not mention the specific type of balloon used in the study methodology [31].

In the current study, the PI did not correlate with the patient's age, sex, or body weight, while a study by Berman et al. identified five features associated with the development of PI following balloon valvoplasty; these include young age, severe degrees of stenosis, large B/A ratio, types of balloon used, and low-pressure gradient following valvoplasty [32] this could be explained by the fact that Berman et al. study recruited young infants with a mean age of 18 days, while the median age in our study was three years.

Pulmonary insufficiency is proven to be a significant problem that increases in frequency with time, reaching a prevalence of 90% [33]. Rao identified B/A ratios to be the most important factor related to the incidence of PI, so he suggested that balloon of 1.2 and 1.25 times the diameter of the PV may result in a better outcomes in pulmonary valvoplasty as compared to the previously recommended ratios of 1.2-1.4 [31], this could explain the relatively high incidence of more than mild PI in current study in 12 out of 45 patients post valvoplasty as the mean B/A ratios in the current study 1.38 ± 0.08 .

Out of the 45 cases included, nine patients (20%) developed complications; these were 6 (13.3%) SVT and 3 (6.7%) Cardiac arrest and CPR. This is lower than that reported by the Parezanovic et al. study, where SVT was reported in (6.8%) of patients, and in addition, there were 4.5% in their study developed ventricular arrhythmia [16]. Weryński et al. [21] reported complications in 3.6% of children following valvoplasty, including one severe complication in the form of a wedge up of a detached balloon

in the femoral vein, which subsequently required surgical intervention. Seven factors have been identified in the current study to be related to the incidence of complications in valvoplasty for severe PS. These include the age of patients, body weight, ET during catheterization, PV annulus size, balloon size, TR severity, and PI severity $P < 0.05$.

No mortality was recorded following transcatheter balloon valvoplasty in children with severe PS in the current study, which matches the results reported by Rao P.S. et al. [34] and Parents et al. who had similar conclusion in a retrospective study at single institution when children underwent a balloon valvoplasty had an excellent long-term outcome and no mortality [35]. These outcomes are better than that registered in previous studies with documented mortality range from 4% to 14% of the treated patients [36,37]. The notable disparity can be attributed to the advanced age bracket of our patients compared to those in these studies.

The current study was not without limitation; it was a retrospective analysis, so documentation and selection bias are unavoidable. There was no data on long follow-ups to see when the stenosis might recur or what the long-term complications could be seen. So, future studies incorporating a longitudinal data for assessing long term outcome are mandatory that will provide a broad picture for long term effectiveness of this procedure. Finally, small sample size and single center setting represent a major limitation as a larger sample multicentric study will probably have better generalizability for patients' results [38-40].

Research involving transcatheter balloon valvoplasty is important since it emphasizes their efficacy as a safe, successful, mini-invasive alternative to open-heart surgery, which is of particular importance to younger patients.

The current study was done by the same cardiologist in the same center, which ensures consistency in technique and reduces the variability of two confounders.

Retrospective studies will give insight into the short-term complications, their associations with patients, and operation factors. This underscores the need for a long patient follow. Having robust data that helps make informed patient decisions upscale our preparedness for possible complications

Conclusion

Transcatheter balloon valvoplasty demonstrates clinical efficacy in the management of severe pulmonary stenosis in pediatric patients. The procedure is not free of complications that correlate with demographical and procedure related factors which highlight the importance of careful patient selection and procedural planning. These insights can guide clinical practice to optimize patient outcomes and minimize procedural risks.

Authors' contribution

MJY (Conceptualization; Data curation; Formal analysis; Investigation; Methodology; Project administration; Vali-

ation; Visualization; Writing – original draft; Writing – review & editing)

SAA (Conceptualization; Formal analysis; Investigation; Project administration)

NNA (Conceptualization; Formal analysis; Investigation; Project administration)

WN (Conceptualization; Formal analysis; Investigation; Project administration; Resources; Supervision; Validation; Visualization; Writing – original draft; Writing – review & editing)

Conflict of interest

None to declare.

References

- Patimang Y. Cyanotic Severe Pulmonary Stenosis with an Intracardiac Shunt: A Case Report and Literature Review. *Gac Med Caracas*. 2024 May 5;132(2).
- Marchini F, Meossi S, Passarini G, Campo G, Pavasini R. Pulmonary valve stenosis: From diagnosis to current management techniques and future prospects. Vol. 19, *Vascular Health and Risk Management*. 2023.
- Hussein MR, Abed MY, Akram NN. Right Ventricular Outflow Tract Perforation and Stenting for a Premature Neonate with Pulmonary Valve Atresia and Double Outlet Right Ventricle. *Mustansiriya Medical Journal*. 2024 Jul;23(2):98–100.
- Heaton J, Horenstein MS, Kyriakopoulos C. Pulmonary Stenosis. 2024.
- Nimmagadda R, Athmakuri KS, Vinjamuri S, Chakravarthy K. Anesthetic Challenges in Severe Pulmonary Stenosis Posted for Caesarean Delivery. *Journal of Obstetric Anaesthesia and Critical Care*. 2024;14(1).
- Costantini P, Perone F, Siani A, Groenhoff L, Muscogiuri G, Sironi S, et al. Multimodality Imaging of the Neglected Valve: Role of Echocardiography, Cardiac Magnetic Resonance and Cardiac Computed Tomography in Pulmonary Stenosis and Regurgitation. Vol. 8, *Journal of Imaging*. 2022.
- Singhi AK, Mohapatra SK, Dey S, Chatterjee D, De A. Challenges in Balloon Pulmonary Valvotomy for Severe Pulmonary Stenosis Presenting with Cyanosis and Ventricular Dysfunction. *Journal of Indian College of Cardiology*. 2022;12(3).
- Otto CM, Nishimura RA, Bonow RO, Carabello BA, rwin JP, Gentile F, et al. 2020 ACC/AHA Guideline for the Management of Patients With Valvular Heart Disease: Executive Summary: A Report of the American College of Cardiology/American Heart Association Joint Committee on Clinical Practice Guidelines. Vol. 143, *Circulation*. 2021.
- Abdulqader S, Nori W, Akram N, Al-Kinani M. Radiological Modalities for the Assessment of Fetal Growth Restriction: A Comprehensive Review. *AL-Kindy College Medical Journal*. 2024 Apr 1;20(1):4–13.
- Castaldi B, Di Candia A, Cuppini E, Sirico D, Reffo E, Padalino M, et al. Percutaneous approach to residual pulmonary bifurcation stenosis in conotruncal diseases. *Cardiol Young*. 2024;34(1).
- He Q, Song M, Huang Y, Wan L. Perioperative care of neonates with critical pulmonary stenosis: Case report. *Medicine (United States)*. 2024;103(8).
- Rao PS. Clinical Case Reports 1992 - 94. *Journal of Medical Case Studies*. 2024;2(1).
- Rao PS, Galal O, Patnana M, Buck SH, Wilson AD. Results of three to 10 year follow up of balloon dilatation of the pulmonary valve. *Heart*. 1998 Dec 1;80(6):591–5.
- Hatem DM, Castro I, Haertel JC, Rossi RI, Zielinsky P, Leboutte FC, et al. [Short- and long- term results of percutaneous balloon valvuloplasty in pulmonary valve stenosis]. *Arq Bras Cardiol*. 2004 Mar;82(3):221–7.
- Cuyper JAAE, Witsenburg M, Van Der Linde D, Roos-Hesselink JW. Pulmonary stenosis: Update on diagnosis and therapeutic options. *Heart*. 2012;99(5).
- Parezanovic V, Djukic M, Dzelebdzic S, Ilisic T, Stefanovic I, Vukomanovic G, et al. Efficacy and safety of balloon valvuloplasty as a treatment of choice for pulmonary stenosis in children and adolescents. *Srp Arh Celok Lek*. 2014;142(9–10):542–6.
- Voet A, Rega F, Van De Bruaene A, Troost E, Gewillig M, Van Damme S, et al. Long-term outcome after treatment of isolated pulmonary valve stenosis. *Int J Cardiol*. 2012;156(1).
- Upadhyay R, Ramteke J, Umbarkar S, Chavan R, Jumley A. Balloon pulmonary valvotomy and anesthesia implications. *The Egyptian Journal of Cardiothoracic Anesthesia*. 2022;16(3).
- Saad MH, Roushdy AM, Elsayed MH. Immediate- and medium-term effects of balloon pulmonary valvuloplasty in infants with critical pulmonary stenoses during the first year of life: A prospective single center study. *J Saudi Heart Assoc*. 2010 Oct;22(4):195–201.
- Karagoz T, Asoh K, Hickey E, Chaturvedi R, Lee KJ, Nykanen D, et al. Balloon dilation of pulmonary valve stenosis in infants less than 3 kg: A 20-year experience. *Catheterization and Cardiovascular Interventions*. 2009;74(5).
- Weryński P, Rudziński A, Król-Jawień W, Kuźma J. Percutaneous balloon valvuloplasty for the treatment of pulmonary valve stenosis in children - A single centre experience. *Kardiol Pol*. 2009;67(4).
- Rao PS. Balloon pulmonary valvuloplasty: A systematic review. Vol. 76, *Indian Heart Journal*. 2024.
- Early Outcome of Balloon Pulmonary Valvuloplasty for Pulmonary Valve Stenosis in Adolescents and Adults: Experience at A Tertiary Care Cardiac Institute. *Annals of Punjab Medical College*. 2020;14(3).
- El-Saeidi SA, Hamza HS, Agha HM, Soliman MM, Attia WA, El-Kaffas R, et al. Experience with balloon pulmonary valvuloplasty and predictors of outcome: A ten-year study. *Cardiol Young*. 2020;
- Fawzy ME, Hassan W, Fadel BM, Sergani H, El Shaer F, El Widaa H, et al. Long-term results (up to 17 years) of pulmonary balloon valvuloplasty in adults and its effects on concomitant severe infundibular stenosis and tricuspid regurgitation. *Am Heart J*. 2007;153(3).
- Mechmèche R, Hadrich M, Boussaada R, Marsit N, Cherif A, Farhati A, et al. Evolution after 5 years of percutaneous pulmonary valvulotomy: report of 47 cases. *Tunis Med*. 2000;78(1).
- Weber HS. Initial and late results after catheter intervention for neonatal critical pulmonary valve stenosis and atresia with intact ventricular septum: A technique in continual evolution. *Catheterization and Cardiovascular Interventions*. 2002;56(3).
- Yin D, Wu X, Xiang P, Zhang Y, Tian J, Lv T, et al. Outcomes of percutaneous balloon pulmonary valvuloplasty in congenital pulmonary valve stenosis. *Clin Case Rep*. 2021;9(9).
- Sharma S, Loya YS, Desai DM, Pinto RJ. Percutaneous double-valve balloon valvotomy for multivalve stenosis: Immediate results and intermediate-term follow-up. *Am Heart J*. 1997;133(1).
- Niewiara Ł, Badacz R, Trębacz J, Kablak-Ziembińska A, Stąpór M, Konstany-Kalandyk J, et al. Rescue balloon aortic valvuloplasty in a patient with cardiogenic shock followed by transcatheter aortic valve implantation. Vol. 81, *Kardiologia Polska*. 2023.
- Rao PS. Role of Balloon Pulmonary Valvuloplasty in the Management of Pulmonary Stenosis. *Clinical Cardiology and Cardiovascular Interventions*. 2021;04(15).
- Berman W, Fripp RR, Raisher BD, Yabek SM. Significant pulmonary valve incompetence following oversize balloon pulmonary valveplasty in small infants: A long-term follow-up study. *Catheterization and Cardiovascular Interventions*. 1999;48(1).
- Hasan BS, Barry OM, Ali F, Armstrong AK, Battivala SP, Crystal MA, et al. Evaluating Procedural Performance: A Composite Outcome for Aortic and Pulmonary Valvuloplasty in Congenital Cardiac Catheterization. *Journal of the Society for Cardiovascular Angiography and Interventions*. 2023;2(6).
- Syamasundar Rao P. Percutaneous balloon pulmonary valvuloplasty: State of the art. *Catheterization and Cardiovascular Interventions*. 2007;69(5).
- Parent JJ, Ross MM, Bendaly EA, Breinholt JP. Results of pulmonary balloon valvuloplasty persist and improve at late follow-up in isolated pulmonary valve stenosis. *Cardiol Young*. 2017;27(8).
- Rima R, Munshi AS, Jabbar A, Khan MdKES. Immediate and Short-Term Results of Balloon Pulmonary Valvuloplasty from Neonates to Grown Up Children with Critical Pulmonary Stenosis: Experience from a Tertiary Care Centre in Bangladesh. *Asian Journal of Pediatric Research*. 2023;13(4).
- Akhani A, Ganjiwale J, Trivedi B, Nimbalkar S. Safety of pediatric cardiac catheterisation procedures performed in rural India in a catheterisation lab setup for adult work. *SCIREA Journal of Clinical Medicine*. 2023;
- Shrivastava S, Shrivastava P. Ameliorating health-care delivery to the vulnerable population groups. *Mustansiriya Medical Journal*. 2019;18(2).
- Faber J, Fonseca LM. How sample size influences research outcomes. *Dental Press J Orthod*. 2014;19(4).
- Hashemi J, Gharahdaghi M, Ansaripour E, Jedi F, Hashemi S. Radiological features of osteoid osteoma: Pictorial review. *Iranian Journal of Radiology*. 2011;8(3).