

CASE REPORT

Ambulatory Treatment of Pressure Sores in a Patient without Neurological Lesions

Anca Cighir*, Paul Antoniu Adrian Boțan

George Emil Palade University of Medicine, Pharmacy, Sciences and Technology, Targu Mures, Romania

Introduction: Pressure sores have been defined as areas of localized soft tissue ischemic necrosis caused by prolonged pressure related to posture, which usually occur over a bony prominence. The most affected areas are those that undergo a lot of tension such as trochanters, sacrum, malleoli, heels and occiput. Most people that are affected by pressure sores have an underlying pathology that makes them immobile, confining them to chairs or bed for longer periods of time. Pressure ulcers may have direct causes (pressure, shear, friction, immobility, loss of sensation) or indirect causes. **Case presentation:** This paper will present the case of a 53-year-old male. After about 3 weeks of being immobilized in bed in dorsal decubitus due to an acute respiratory distress which required intubation and mechanical ventilation, the patient developed very large pressure sores on the left sacral and buttock area and left sole. He was treated in the outpatient department using multiple therapeutic protocols based on the alternation of antibiotic creams and modern absorbent dressings. **Conclusions:** The evolution of this patient was long but favorable, the left sacral and buttock area eschar closing completely while the sole eschar had a good evolution, but is still undergoing treatment.

Keywords: pressure sores, immobilization, modern absorbent dressings

Received 7 July 2020 / Accepted 23 August 2020

Introduction

The earliest mention of pressure sores dates far back to almost 5000 years ago when they were found in Egyptian mummies and treated using honey or other topical remedies such as moldy bread, meat or animal and plant extracts [1]. In the 19th century, Jean-Martin Charcot attested the *neurotrophic theory*, but was later contradicted by Brown-Sequard who proved that *pressure* is the cause [1]. Nowadays, etiology theories and treatment methods have evolved, allowing a better understanding of this affection.

Pressure sores have been defined as areas of localized soft tissue ischemic necrosis caused by prolonged pressure higher than the capillary pressure related to posture which usually occur over a bony prominence [1]. The areas that are most affected are those that undergo a lot of pressure such as trochanters, sacrum, malleoli, heels and occiput [2].

The usual amount of pressure the arterial side of a capillary can sustain for a short period of time is around 30-32 mmHg. Any increase over this pressure can lead to occlusion and initiate the ischemia, tissue death and ulceration [3]. Besides the occlusion of the blood flow, the tissue damage causes an obstruction of the lymphatic flow which leads to metabolic waste products, proteins and enzymes accumulation [4]. A large amount of pressure leads to a pressure sore in a shorter time, while a small amount takes a longer time to cause damage [2]. Pressure ulcers may have direct causes or indirect causes [2].

Direct causes

- Pressure [5];
- Shear;
- Friction [6];
- Immobility [2].

Indirect causes

- Physiological changes related to age - weakening of the blood vessel walls and connective tissue and loss of fat and muscle;
- Conditions associated with prolonged wound healing such as diabetes mellitus [2];
- Any disease causing a low oxygen level in the blood such as chronic obstructive pulmonary disease, cardiac failure, myocardial infarction [2];
- Malnutrition may lead to hypoproteinemia and anemia causing a delay in the wound healing process [7];
- Moisture [5];
- Mental health conditions – due to the poor diet and neglect of personal hygiene.

The severity of the pressure ulcers can be assessed using the EPUAP (European Pressure Ulcer Advisory Panel) grading system, which classifies them into four categories [2].

Grade 1 is characterized by erythema, edema, induration and warmth in a specific area for pressure sores without any open lesions.

In grade 2, both the epidermis and the dermis is affected (partial skin loss). The wound on the surface of the skin is either a blister or an open wound.

Grade 3 - the entire thickness of the skin is affected by the necrosis; muscles and bones are not involved.

Grade 4 – the most severe type. The full thickness of

* Correspondence to: Anca Cighir
E-mail: cighir_anca@yahoo.com

the skin is destroyed by the necrotic process, along with the surrounding tissues, muscles, bones, joint capsules or tendons.

The treatment of pressure ulcers includes preventing infections, surgical removal of the dead tissues, reducing the pressure on the affected skin and local dressings.

This paper will present the case of a 53-year-old male patient focusing mostly on the clinical aspect of the wound and the original treatment applied in the Plastic Surgery Department of the Clinical County Hospital of Targu Mures.

Case presentation

The article follows the case of a 53-year-old male patient who suffers from obesity, chronic tabagism and essential hypertension.

He developed an acute respiratory distress after a cold which required intubation and mechanical ventilation. After about 3 weeks of being immobilized in bed in dorsal decubitus, due to the prolonged and increased pressure and

associated pathologies, the patient developed very large pressure sores on the left sacral and buttock area (grade 4) and the external half of the left sole (grade 2 and 3).

A very large wound of about 15 cm/22 cm appeared on the left buttock with irregular borders and extensive undermining following a full-thickness necrosis that has been previously excised on behalf of forceps and scissors (Figure 1A). The bottom of the wound shows a lot of fibrin and adherent slough, alternating with a very thin layer of granulation tissue.

The patient was treated in the outpatient department using multiple *local therapeutic protocols* based on the alternation of *antibiotic creams* (silver sulfadiazine cream 10 mg/g and povidone-iodine cream 100 mg/g) and *modern absorbent dressings* (polyurethane foam dressings – PUR-foam and nitrocellulose dressings).

PUR-foam is a synthetic foam made from polyurethane. It has a “honeycomb” spatial structure (containing 96-98% air), making it very elastic. When applied, it does a permanent micro-massage of the vascular structures in

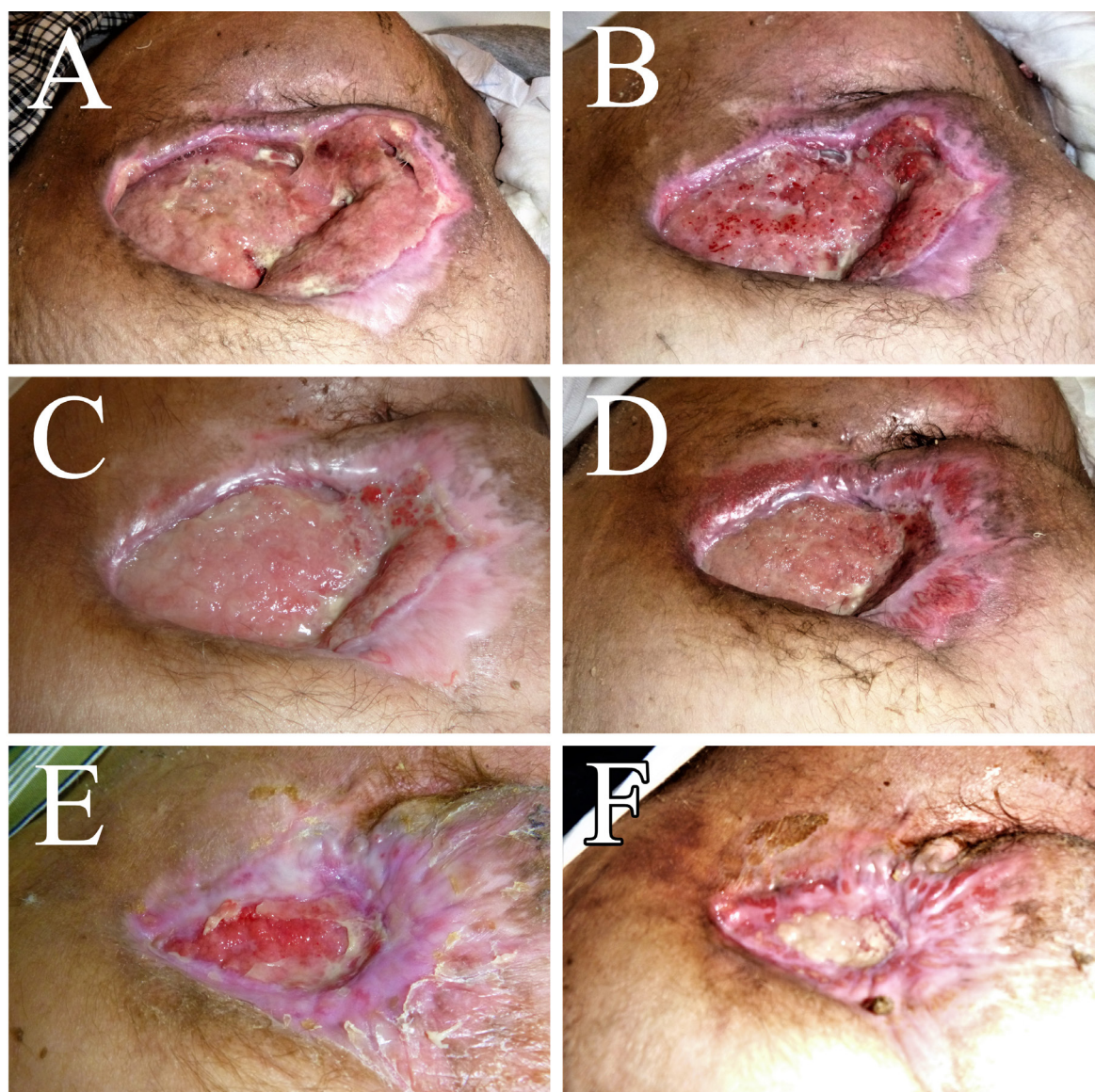


Fig. 1. One can see the initial aspect of the wound on the left buttock and sacral area (A), the evolution of the lesion during the autolytic debridement (B, C), the formation of the granulation tissue (D, E) and the final aspect after several months of conservative treatment (F).

the wound bed stimulating exudation, capillary budding, vasodilation and consequently enhancing oxygen and nutrient intake.

The first step of the local treatment was the *autolytic debridement* of the lesion. The wound was covered with antibiotic creams (alternating silver sulfadiazine and povidone-iodine creams) and then plugged with several layers of polyurethane foam dressings which helped to absorb the slough and fibrin deposits and to promote the development of granulation tissue (Figure 1B). The dressings were changed every time they were soaked with exudate.

A close image of the wound during the debridement process can be seen in Figure 1C, showing a lot of exudate covering the granulation tissue that began to fill the bottom of the wound. Unfortunately, this good local evolution has been stopped for 2-3 weeks because a spontaneous rupture of the inferior gluteal artery occurred while the patient was at home, resulting in brisk bleeding and severe post-hemorrhagic anemia, requiring surgical hemostasis and emergency treatment in the ICU unit.

After the patient was stabilized, he returned to our department to resume the local treatment of the pressure sores. The wound began to shrink as the bottom was filled

with new granulation tissue and the exudate decreased significantly (Figure 1D).

After a few weeks of alternating polyurethane foam dressings with nitrocellulose absorbent dressings, a very good granulation bed was formed – red granulation tissue bordered by a thin layer of new epithelium (Figure 1E).

The aspect of the lesion after several months of conservative treatment using nitrocellulose dressings and polyurethane foam dressings can be seen in Figure 1F. The sacral eschar is almost closed with small granulation tissue remaining in the central part of the former wound.

He also developed an eschar of about 22 cm/11 cm on the lateral margin of the left sole, with irregular borders and an extensive undermining of the skin (affecting the epidermis, dermis and soft tissues) and initially covered by a necrotic tissue.

The pressure sore was debrided, all slough and fibrin deposits being removed by the same absorbent dressings mentioned above (Figure 2A). A good granulation tissue began to develop on the wound surface and the wound margins were covered by a thin new epithelium (Figure 2 B,C).

Figure 2D is significant for the absorbent properties of polyurethane foam dressings. Usually, the dressings have to

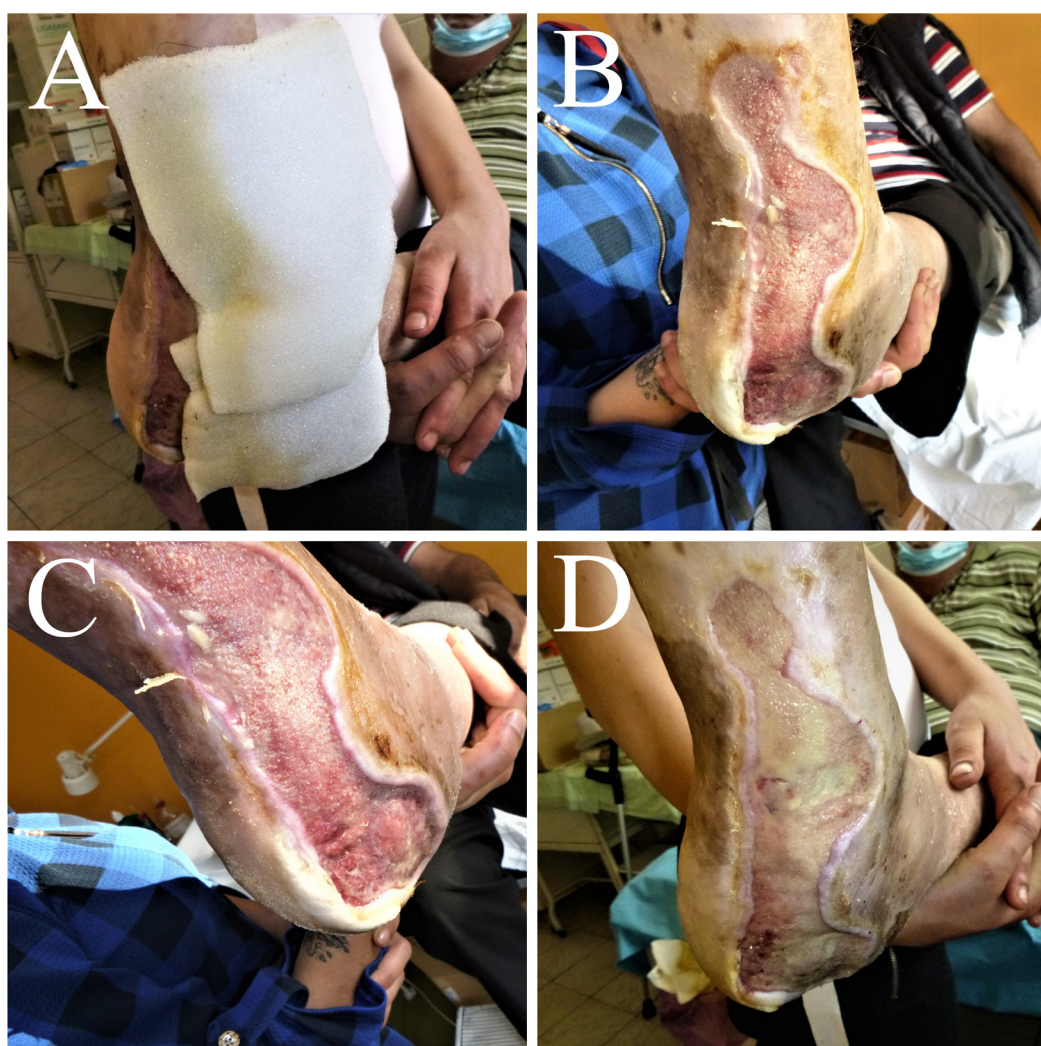

Fig. 2. The pressure sore of the lateral margin of the left sole (A). Polyurethane foam dressings were applied, leading to the formation of the granulation tissue (B,C). Because of a delay in treatment, the newly formed granulation tissue was covered with fibrin deposits (D).

be changed 2-3 times a week, but for unknown personal reasons the treatment was delayed, therefore, a rich fibrin deposit appeared on the wound surface. This case is still under treatment for the remaining plantar wound, but the evolution so far was good.

There was no *systemic* treatment, except for wide spectrum antibiotics and volemic resuscitation when the gluteal artery hemorrhage occurred.

In order to reduce pressure and avoid the formation of other pressure sores, the patient was advised to change his position often and use support surfaces such as mattresses or pillows.

The evolution of this patient was long but favorable, the left sacral and buttock area eschar closing completely and leaving a recent, evolutive scar which will disappear in the next few months.

The patient was completely immobilized into a wheelchair for a few months, but he steadily regained his walking ability using an orthopedic cane. Due to the fact that he is overweight, the sole eschar healed at a slower pace but it also had a good evolution.

To be noted that the patient had to do his own dressings during the emergency state caused by Covid-19 (using daily or every two days nitrocellulose dressings). After all medical offices began working again, he came to the Plastic Surgery outpatient Department for the local treatment mentioned above.

Conclusions

Pressure ulcers are a commonly found pathology in patients with a lot of associated comorbidities who are forced to stay in bed for longer periods of time. Therefore, a well-established therapeutic protocol is extremely important. Due to the fact that most of these patients, like the one presented in this paper, have cardiovascular or respiratory problems, a local, conservative treatment is the best option, as they can't undergo local or spinal anesthesia.

The treatment presented in this paper consisted of local alternative dressings using antibiotic creams and modern dressings - which encouraged the formation of granulation tissue and spontaneous epithelialization - and methods to alleviate pressure.

All procedures were done ambulatory and allowed the patient to treat himself at home when medical services were not available.

Authors' contribution

C.A. (Data collection and analyzing; Conceptualization; Writing – original draft)

B.A. (Study coordinator; Conceptualization; Writing – supervision, review & editing)

Conflicts of interest

None to declare.

Informed consent

An informed consent was signed by the patient.

References

1. Agrawal K, Chauhan N. Pressure ulcers: Back to the basics. *Indian J Plast Surg.* 2012 May;45(2):244-54;
2. Bhattacharya S, Mishra RK. Pressure ulcers: Current understanding and newer modalities of treatment. *Indian J Plast Surg.* 2015 Jan-Apr;48(1):4-16;
3. Callam MJ, Ruckley CV, Harper DR, Dale JJ. Chronic ulceration of the leg: extent of the problem and provision of care. *Br Med J (Clin Res Ed).* 1985 Jun 22;290(6485):1855-6;
4. Krouskop TA, Reddy NP, Spencer WA, Secor JW. Mechanisms of decubitus ulcer formation--an hypothesis. *Med Hypotheses.* 1978 Jan-Feb;4(1):37-9;
5. Dodd KT, Gross DR. Three-dimensional tissue deformation in subcutaneous tissues overlying bony prominences may help to explain external load transfer to the interstitium. *J Biomech.* 1991;24(1):11-19;
6. Allman RM. Pressure ulcer prevalence, incidence, risk factors, and impact. *Clin Geriatr Med.* 1997 Aug;13(3):421-36;
7. Scivoletto G, Fuoco U, Morganti B, Cosentino E, Molinari M. Pressure sores and blood and serum dysmetabolism in spinal cord injury patients. *Spinal Cord.* 2004 Aug;42(8):473-6.