

RESEARCH ARTICLE

Ethanollic extract of Edamame (*Glycine max* L. merril) enhance second degree burn wound healing trough modulating of hydroxyproline levels and increasing epithelial thickness

Ika Rahmawati Sutejo*, Arifah Nur Hasanah, Faizah Ramadhani Sudarko

Faculty of Medicine, University of Jember, East Java, Indonesia

Objective: Burns has become a global health problem because it causes about 180.000 deaths worldwide every year. In developing countries, silver sulfadiazine cream is usually used as drug management for second-degree burns, but it is expensive, so several herbal treatments have developed recently. The seed of edamame has genistein compounds that can increase collagen synthesis. The antioxidant component also enhances the burn wound healing process. The study aims to prove the effectiveness of ethanollic extract of edamame's seed in the second-degree burn wound healing process. **Methods:** Burn wound was made by applying hot aluminum (70 °C) coin on the skin rat. The negative control group (C-) was given Na-CMC 0.5%, the positive control group (C+) was given cream silver sulfadiazine, the treatment groups T1, T2, T3, and T4 were given an ethanollic extract of edamame with the concentration of 20%, 40%, 60%, and 80% for 15 days. Hydroxyproline levels were evaluated by hydroxyproline biochemistry assay, the epithelial thickness was observed on histopathological preparations with HE staining. **Results:** The results showed that the hydroxyproline levels on the 16th were modulated, while epithelial thickness was higher in the treatment group than in the control group (P<0.05). **Conclusions:** We conclude that the certain concentration of ethanollic extract of edamame (*Glycine max* L. Merrill) was effectively enhanced the second-degree burn wound healing by modulating hydroxyproline levels and increasing epithelial thickness.

Keywords: second-degree burn, hydroxyproline, epithelial thickness, edamame seed, wound healing

Received 10 November 2021 / Accepted 2 May 2022

Introduction

Burns become a global health problem because it causes about 180,000 deaths worldwide each year [1]. The prevalence of second-degree burn was 73% of all burn cases [2]. Burns have a lot of kinds and different treatments based on the type of tissue, the extent of damage, and the complications [3]. In developing countries, burns treatment usually uses cream silver sulfadiazine to help wound healing because of its antimicrobial effects. However, the previous study indicates that the compound of cream silver sulfadiazine delays the wound healing process [4]. And the silver may have cytotoxic activity on various cells [5]. Because of this, burn treatments are currently being developed for natural medicines preparation [6]. Edamame's seed extract might become an alternative treatment for a burn.

Edamame (*Glycine max* L. Merrill) is a primary commodity of the Jember Regency of East Java, Indonesia. It was known as vegetable soybean because it is harvested young and green, namely at the R-6 or R-7 growing stage. This stage is when the seed filling is almost full, about 80-90% of the maximum pod size, 60-65 days after planting. In comparison, grain soybean has a harvest period at stage R-8 [7]. Edamame seed contains carbohydrates, protein, calcium, and phosphor [8]. It also contains isoflavones, saponins, vitamins A, C, and E [9, 10]. In edamame, iso-

flavones, genistein, and saponins act as antioxidants, anti-inflammatory, and antimicrobials that benefit wound healing [11, 12]. Vitamins in edamame can reduce and prevent oxidative damage and improve wound healing [9, 10].

This study aims to prove the wound healing activity of edamame's seed ethanollic extract (*Glycine max* L. Merrill) in a second-degree burn. The wound healing process is partitioned into three phases: inflammation, proliferation, and maturation. The proliferative phase lasts for 3-21 days, depending on the extent of injury [13]. There are several processes of migrating fibroblasts in this phase, collagen synthesis, angiogenesis, granulation tissue formation, and epithelialization [14]. The treatment was carried out for 15 days representing wounds condition during the end of the proliferation phase. The parameters of the wound healing process in this research are hydroxyproline levels and epithelial thickness. Hydroxyproline levels represent the concentration of collagen. In the early phase, a higher hydroxyproline concentration indicates a quicker pace of healing wounds [15]. Epithelialization is the process of re-closing the injured skin surface. Wound healing epithelialization can be observed by increasing epithelial thickness [16].

Material and Methods

Ethanollic extract of edamame

Extract of edamame seed was macerated with ethanol. 730-gram edamame seed powder dissolved in 96% ethanol

* Correspondence to: Ika Rahmawati Sutejo
E-mail: ikarahmawati.fk@unej.ac.id

for 3 days, then filtered to separate the filtrate and residue. The collected filtrate was evaporated at 50 °C using a rotary evaporator. It was obtained edamame extract with a weight of 98.7 grams. Ethanolic extract of edamame seed was diluted in 0.5% Na-CMC, then it was made the final concentration of 20%, 40%, 60% and 80%.

Animals

Rat (*Rattus Norvegicus*, Wistar strain) utilized in this study was set in the Pharmacology Faculty of Medicine laboratory, University of Jember. Twenty four male Wistar rats weighing 150-250 grams were taken by simple random sampling. The animal was placed in individual cages (an animal each) at room temperature. They were fed and water ad libitum. The ethics team of the Faculty of Medicine, University of Jember has approved this research with ethical approval No. 1190/H25.1.11/KE/2019 on 6 November 2019.

Experimental design

This research was true experimental laboratories research with posttest only control group design. Twenty-four samples were divided into 6 groups: negative control group (C-), positive control group (C+), T1 treatment group, T2 treatment group, T3 treatment group, and T4 treatment group. The negative control group (C-) was given Na-CMC 0.5%, the positive control group (C+) was given cream silver sulfadiazine. The treatment groups T1, T2, T3, and T4 were given an ethanolic extract of edamame with concentrations of 20%, 40%, 60%, and 80% for 15 days.

Second-degree burn

Second-degree burns are made by attaching hot coins to the backs of mice that have been shaved off. The hot coin was obtained by heating the coins to 70 degrees centigrade in a dry oven fire for 5 minutes, then attached to the rats' back for 10 seconds. Previously rats were anesthetized with ketamine concentration of 40-100 mg/kg BW and xylazine dose 5-13 mg/kg BW intraperitoneally [17].

Treatment of second-degree burn

After the skin of rats is burned, the wound is cleaned with normal saline. Then, the rats were given treatment according to the group. Areas that have been given extract, covered with gauze. Try to prevent scratching, removing, eating, or licking extracts that have been applied. Treatment was done once a day for 15 days. The animals were terminated using anesthesia ether.

Measurement of hydroxyproline level

The skin of the scar tissue was taken 300-500 mg, placed on a petri dish, and dried at 60 °C for 12 hours. 3-5 mL of 6 N HCl were added. The skin tissue is hydrolyzed at 130 °C for 4 hours. The 2 mL solution from the hydrolysis process was transferred to an Eppendorf tube and separated

using a centrifuge at 10.000 rpm for 5 minutes. The resulting supernatant was transferred and evaporated for 30-45 minutes at 60-80 °C. 500 µL of the evaporated solution were added with 30 µL Chloramine T and 470 µL buffer citrate pH 6. The resulting mixture was incubated for 20 minutes at room temperature. The reaction was terminated by adding 250 µL of 0.4 M HClO₄ and 250 µL Ehrlich reagents. The mixture was incubated for 90 minutes at 60 °C, centrifuged with the speed of 3000-4000 rpm for 5 minutes, then transferred to a cuvette. Hydroxyproline levels were measured at a wavelength of 557 nm using a spectrophotometer. The amount of hydroxyproline in the sample was calculated against the standard curve of L-hydroxyproline [3].

Epithelial thickness measurement

This histopathological preparation used HE staining. Epithelial thickness examination is done by measuring the thickness of the epithelium from the stratum basalis to the stratum corneum using an Olympus BX53 microscope with 100 times magnification assisted with Optilab and Raster image software. The thickest and the thinnest epithelium were measured in one selected visual field, and the results were averaged.

Statistical analysis

The data were tested for normality and homogeneity of variance. The data analysis used was one-way ANOVA to determine the difference of wound healing process between groups and followed by a Post hoc LSD test to find out significantly different between groups ($p < 0.05$).

Results

The macroscopic wound was documented in this study to differentiate the treatment between groups. The documentation was taken on the 5th, 11th, and 16th days. The healing process of the wound can be seen in Figure 1. The picture shows faster wound healing in the treatment group, with a diameter smaller than the control group on the 16th day. The treatment group T3, with an extract concentration of 60%, showed the greatest reduction in wound area compared to other treatment groups and the silver sulfadiazine group.

Table I presents hydroxyproline levels on 16th day of the treatment group with extract 20%, 40%, 60%, and 80% were 3210.5 ± 419.63 ; 1708.5 ± 794.83 ; 1820.5 ± 721.54 ; and 648 ± 375.45 µg/100 mg. Based on these results, ethanolic extract of edamame modulated hydroxyproline levels. The hydroxyproline levels increase up to the extract with a concentration of 60%. At the concentration of 80%, hydroxyproline levels were lower. The silver sulfadiazine group had 970.5 ± 473.10 µg/100 mg hydroxyproline levels.

Ethanolic extract of edamame increased epithelial thickness in the second-degree burn healing process compared to the negative control group (Figure 2). The epithelial

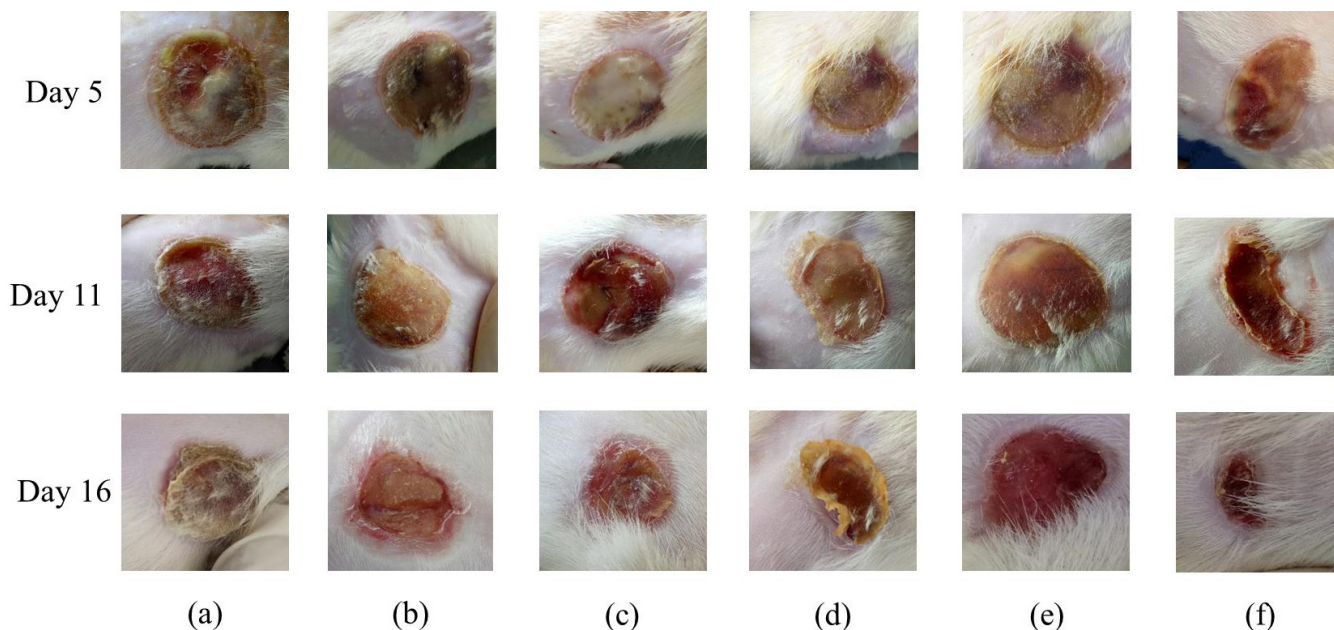


Fig. 1. The wound healing process. (a) Negative control group; (b) Group T1 with extract concentration of 20%; (c) Group T2 with extract concentration of 40%; (d) Group T3 with extract concentration of 60%; and (e) Group T4 with extract concentration of 80%; (f) Positive control (Silver sulfadiazin) group.

Table I. Wound healing parameters

Treatment group	Concentration extract (%)	Hydroxyproline levels (µg/100 mg ± SD) (n=4)	Epithelial thickness (µm ± SD) (n=4)
Control Negative	0	2193 ± 992.53	93.268 ± 14.061
Treatment1 (T1)	20	3210.5 ± 419.63*	147.694 ± 30.378*
Treatment2 (T2)	40	1708 ± 794.83	208.777 ± 41.915*
Treatment3 (T3)	60	1820.5 ± 721.54	144.607 ± 24.770
Treatment4 (T4)	80	648 ± 375.45**	96.560 ± 44.481
Control Positive	SS	970.5 ± 473.10*	167.277 ± 46.440**

*: significantly different compared to K- (p<0.05); **: significantly different compared to K- (p<0.01); SS : silver sulfadiazine

thickness on 16th day of the treatment group with extract concentration of 20%, 40%, 60%, and 80% were 147.694 ± 30.378; 208.777 ± 41.915; 144.607 ± 24.770; and 96.560 ± 44.481 µm. The negative control group had

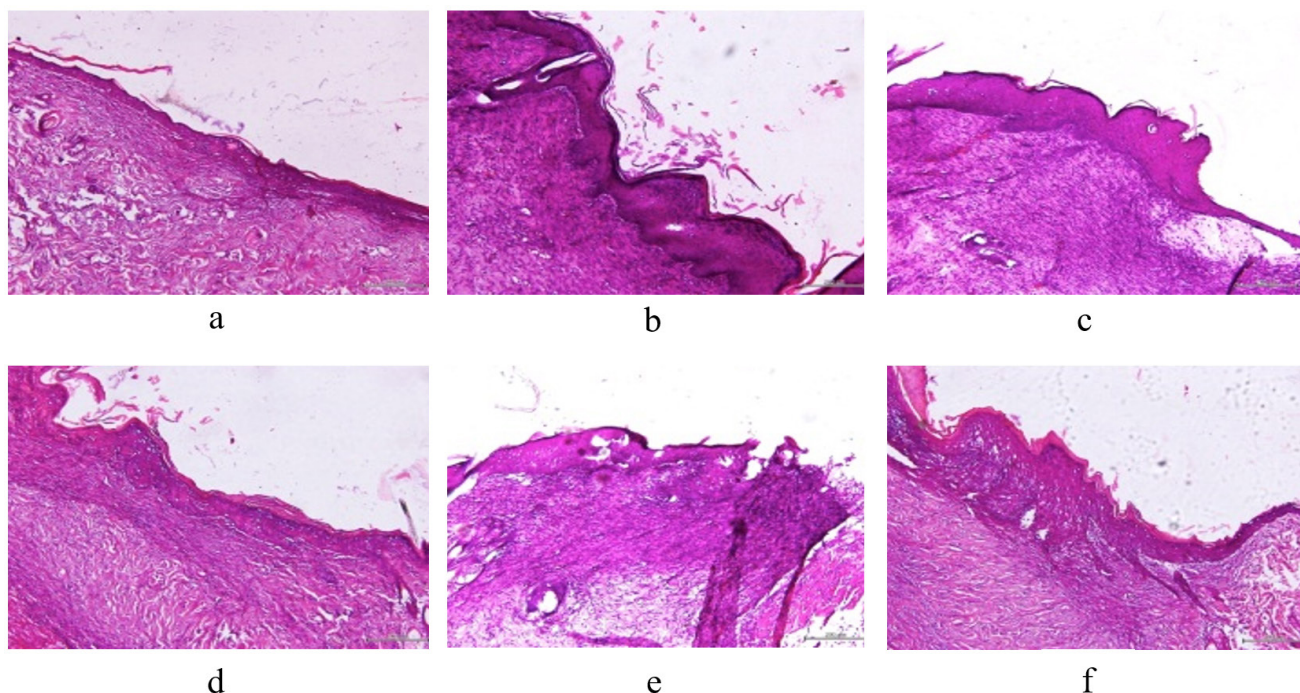


Fig. 2. Microscopic evaluation of wound healing process. a) Negative control group; (b) Group T1 with concentration extract of 20%; (c) Group T2 with concentration extract of 40%; (d) Group T3 with concentration extract of 60%; and (e) Group T4 with concentration extract of 80%; (f) Positive control (Silver sulfadiazin) group.

the thinnest epithelial thickness of $93.268 \pm 14.061 \mu\text{m}$. The silver sulfadiazine group had an epithelial thickness of $167.277 \pm 46.440 \mu\text{m}$.

Discussion

Ethanol extract of edamame modulated hydroxyproline levels. In the early phase, a higher hydroxyproline concentration indicates a quicker pace of healing wounds [15]. Then hydroxyproline levels depressed at the end of the wound healing process. In this study, hydroxyproline levels rise with an increasing dose, up to the extract with a concentration of 60%. It means that the healing process in the 20% to 60% extract group occurred faster than usual. Previous research concluded that hydroxyproline levels would increase during the wound healing process and will decrease when the healing process ends [18].

Modulating hydroxyproline levels in wound healing is caused by edamame extract containing isoflavones and saponins. Isoflavones have antioxidant, antimicrobial, and anti-inflammatory effects [19]. Three types of isoflavones are daidzein, glycitein, and genistein. Genistein controls wound healing by changing the inflammatory response through antioxidant effects. Genistein manages NF- κ B and TNF expression during the early phase of the wound healing process [11]. Genistein inhibits oxidative stress by increasing antioxidant activity and managing the expression of pro-inflammatory cytokines during wound healing [11]. Saponins also have antioxidant, anti-inflammatory, and antimicrobial effects [12].

Edamame also contains vitamins A, C, and E. Vitamin A plays a role in improving the wound inflammatory response. Vitamin C, a cofactor of the proline-4-hydroxylase enzyme, acts as a proline catalyst to hydroxyproline [20, 21], plays an essential role in the strength and stability of collagen fibers. In addition, vitamin C also improves neutrophil function and has antioxidant effects [22]. Vitamin E is an antioxidant with anti-inflammatory effects and accelerates wound healing [23].

Reepithelialization recovers the injured skin surface [16]. Keratinocytes are cells that play a role during reepithelialization [24]. The migration and proliferation of keratinocytes in the process of re-epithelialization is controlled by several growth factors, such as fibroblast growth factor (FGF), epidermal growth factor (EGF), and transforming growth factor- β (TGF- β) [6]. Ethanol extract of edamame increased epithelial thickness in the second-degree burn healing process compared to the negative control group. Genistein and saponins affect growth factors such as TGF- β 1 and IGF-1, thus accelerating keratinocyte migration in the process of re-epithelialization [25]. Flavonoids also play a role in spurring the process of mitogenesis, cell interaction, and molecular adhesion to the epithelialization process in the wound healing process [26]. At the same time, saponins have roles in enhancing epithelialization and closure of wounds [27]. Saponins can also increase TGF- β , which will bind to fibroblasts in collagen

synthesis. Collagen is an extracellular matrix as the basis for the keratinocyte migration process, so increased matrix formation can induce epithelialization [28].

Arwiyah's study (2013) stated that the new epithelial formation on wound healing could be observed from day 14 to 21 days. The treatment of burns in this research was done for 15 days, and epithelial thickness was evaluated on the 16th day [29]. It must be the end stage of proliferation turn to the maturation phase. The epithelial thickness of the group with a concentrated extract of 40% was thickest. It indicates that the healing process in this group occurs more rapidly than in the other groups. At observation, the wound has entered the remodeling and resolution phase. In the resolution phase of healing, the cell number is dramatically reduced by apoptosis of vascular cells, macrophages, and myofibroblasts [16]. This explanation supported macroscopic evaluation shows that the 40% extract concentration treatment group delivered one of the best reductions in wound area.

In contrast, the 80% concentration extract group shows the lowest hydroxyproline levels and epithelial thickness. Researchers suppose two possibilities. First, there is a delay in the healing process, and second, there is an acceleration of the wound healing process and has entered the resolution phase. The researchers compared this data with the macroscopic wound evaluation and the epithelial thickness. We concluded that the healing process of the T4 group was inhibited because the macroscopic evaluation shows that this group had the lowest reduction in wound area compared to the other groups and the thickness of the epithelium was not significantly different from the negative control group.

The phytoestrogen component on edamame, such as genistein and daidzein, has a biphasic effect on its concentration or dosage [30, 31, 32]. They induce biologically opposite effects at different doses. At the low dose, genistein works as an agonist at the estrogen receptor locus, whereas at higher doses, genistein is less effective and may even have adverse effects on bone and cancer cells [31, 32]. On enhancing second-degree burn wound healing, at the low concentration, genistein was adequate, but it may have potentially adverse effects at the higher concentration.

Silver sulfadiazine is a topical standard gold treatment for burns and acts as an antibacterial [33] so that it was used as the treatment of the positive control group. The silver content of silver sulfadiazine has a preventive effect by blocking microorganisms such as fungi. Silver sulfadiazine can also inhibit the metalloproteinase matrix and increase epithelialization, thus accelerating wound healing [34]. Silver sulfadiazine can invigorate cells such as macrophages to produce growth factors and cytokines in wound healing processes like TGF- β , EGF, IL-1, IL-4, and IL-8, along with antibacterial properties, can speed up the wound healing process [35]. By the results of this study, the wound on the silver sulfadiazine group healed faster than the other group due to the macroscopic evaluation showing that this

group had the best reduction in the wound. The concentration of hydroxyproline and the thickness of epithelium in this group also support the healing process entering the final stage.

Conclusion

It can be concluded that ethanolic extract of edamame's seed (*Glycine max* L. Merrill) in a certain concentration effectively enhances second-degree burn wound healing by modulating hydroxyproline levels and increasing epithelial thickness. Edamame contains isoflavones, genistein, saponins, vitamins A, C, and E act as antioxidants, anti-inflammatory, and antimicrobials that benefit wound healing. Serial measurement of the parameters at multiple time point will reinforce result of this study.

Author contributions

IRS: (Conceptualization; Conception and design; Supervision; Data interpretation; writing & revising of the manuscript) ANH: (Literature search; Data collection; Data analysis) FRS: (Literature search; Data collection; Data analysis)

Conflict of interest

None to declare.

References

- Ghebreyesus TA. Burns. <http://www.who.int/mediacentre/factsheets/fs365/en/>. 2017. [accessed on 26th of September 2021].
- Sarabahi S. Principles and Practice of Burn Care. 1st ed. New Delhi: Jaypee Publishers, 2010.
- Rismana EI, Rosidah PY, Bunga EY. Efektivitas khasiat pengobatan luka bakar sediaan gel mengandung fraksi ekstrak pegagan berdasarkan analisis hidrosiprolin dan histopatologi pada kulit kelinci. *Buletin Penelitian Kesehatan*. 2013; 41(1): 45-60.
- Cho Lee AR, Leem H, Lee J, Park KC. Reversal of silver sulfadiazine-impaired wound healing by epidermal growth factor. *Biomaterials*. 2005 Aug;26(22):4670-6. doi: 10.1016/j.biomaterials.2004.11.041. Epub 2005 Jan 13. PMID: 15722137.
- Fraser JF, Cuttle L, Kempf M, Kimble RM. Cytotoxicity of topical antimicrobial agents used in burn wounds in Australasia. *ANZ J Surg*. 2004 Mar;74(3):139-42. doi: 10.1046/j.1445-2197.2004.02916.x. PMID: 14996161.
- Isrofah & Afandi SM. Efektifitas salep ekstrak daun binahong (*Anredera Cordifolia* (Ten) Steenis) terhadap proses penyembuhan luka bakar derajat 2 termal pada tikus putih (*Rattus Novergicus*). *Muhammadiyah Journal of Nursing*. 2015; 27-36.
- Konovsky J, Lumpkin TA, and McClary D. 1994. Edamame: The Vegetable Soybean. Washington State University. 1-9
- Amar WS & Lutfiati D. Pengaruh penggunaan minyak kedelai dan susu skim terhadap organoleptik pasta kedelai edamame. *Ejournal boga*. 2013; 2(1): 139-149.
- Widati F & Hidayat IM. Kedelai Sayur (*Glycine max* L. Merrill) sebagai Tanaman Pekarangan. Bandung: Balai Penelitian Tanaman Sayuran, 2012.
- Kanchana P, Santha ML, Raja KD. A review on *Glycine max* L. Merrill (soybean). *World Journal of Pharmacy and Pharmaceutical Sciences*. 2015; 5(1): 356-371.
- Kong AT. Inflammation, Oxidative Stress, and Cancer: Dietary Approaches for Cancer Prevention. 1st ed. Florida: CRC Press, 2014.
- Moses T, Papadopoulou KK, & Osbourn A. Metabolic and functional diversity of saponins, biosynthetic intermediates and semi-synthetic derivatives. *Critical Review Biochemistry and Molecular Biology*. 2014; 49(6): 439-462. DOI: 10.3109/10409238.2014.953628
- Brown A. Wound management 1: phases of the wound healing process. *Nursing Times*. 2015, 11: 46, 12-13.
- Velnar T, Bailey T, and Smrkolj V. The wound healing process: an overview of the cellular and molecular mechanisms. *The Journal of International Medical Research*. 2009; 37(5): 1528-1542. DOI: 10.1177/147323000903700531
- Dwivedi D, Dwivedi M, Malviya S, & Singh V. Evaluation of wound healing, anti-microbial and antioxidant potential of *Pongamia pinnata* in wistar rats. *Journal of Traditional and Complementary Medicine*. 2017, 7(1): 79-85. <https://doi.org/10.1016/j.jtcm.2015.12.002>
- Pastar I, Stojadinovic O, Yin NC, Ramirez H, Nusbaum AG, Sawaya A, Patel SB, Khalid L, Isseroff RR, Tomic-Canic M. Epithelialization in Wound Healing: A Comprehensive Review. *Adv Wound Care (New Rochelle)*. 2014 Jul 1;3(7):445-464. doi: 10.1089/wound.2013.0473.
- Venter NG, Monte-Alto-Costa A, Marques RG. A new model for the standardization of experimental burn wounds. *Burns*. 2015 May;41(3):542-7. doi: 10.1016/j.burns.2014.08.002.
- Caetano GF, Fronza M, Leite MN, Gomes A, Frade MA. Comparison of collagen content in skin wounds evaluated by biochemical assay and by computer-aided histomorphometric analysis. *Pharm Biol*. 2016 Nov;54(11):2555-2559. doi: 10.3109/13880209.2016.1170861.
- Yu J, Bi X, Yu B, & Chen D. Isoflavones: anti-inflammatory benefit and possible caveats. *MDPI Journals*. 2016; 8(6): 1-16. DOI: 10.3390/nu8060361
- Darma S, Manjas M, Saputra D, Agus S, & Eradius. Efek pemberian suntikan vitamin c terhadap luka insisi dermal. *Jurnal Kesehatan Andalas*. 2013; 2(3): 168-169. DOI: <https://doi.org/10.25077/jka.v2i3.247>
- Affah SP. Validasi Metode Penetapan Kadar Asam Amino Hidrosiprolin Menggunakan Metode Spektrofotometri UV-Vis. Skripsi. Tidak dipublikasikan. Jakarta: Fakultas Kedokteran dan Ilmu Kesehatan UIN Syarif Hidayatullah Jakarta, 2016.
- Chow O & Barbul A. Immunonutrition: role in wound healing and tissue regeneration. *Adv Wound Care*. 2014; 3(1):46-53. DOI: 10.1089/wound.2012.0415
- Tanaydin V, Conings J, Malyar M, van der Hulst R, van der Lei B. The Role of Topical Vitamin E in Scar Management: A Systematic Review. *Aesthet Surg J*. 2016 Sep;36(8):959-65. doi: 10.1093/asj/sjw046.
- Reinke JM, Sorg H. Wound repair and regeneration. *Eur Surg Res*. 2012;49(1):35-43. doi: 10.1159/000339613.
- Salehi B, Azzini E, Zucca P, Maria Varoni E, V. Anil Kumar N, Dini L, Panzarini E, Rajkovic J, Valere Tsouh Fokou P, Peluso I, Prakash Mishra A, Nigam M, El Rayess Y, El Beyrouthy M, N. Setzer W, Polito L, Iriti M, Sureda A, Magdalena Quetglas-Llabrés M, Martorell M, Martins N, Sharifi-Rad M, M. Estevinho L, Sharifi-Rad J. Plant-Derived Bioactives and Oxidative Stress-Related Disorders: A Key Trend towards Healthy Aging and Longevity Promotion. *Applied Sciences*. 2020; 10(3):947. <https://doi.org/10.3390/app10030947>
- Pratiwi AD, Ratnawati R, and Kristanto H. Pengaruh pemberian ekstrak kuncup bunga cengkeh (*Syzygium aromaticum*) terhadap peningkatan ketebalan epitelisasi luka insisi pada tikus putih (*Rattus novergicus*) galur wistar. *Majalah Kesehatan FKUB*. 2015; 2(3): 135-143.
- Thakur R, Jain N, Pathak R, & Sandhu SS. Practices in wound healing studies of plants. *Evidence-Based Complementary and Alternative Medicine*. 2011; 1-17. DOI: 10.1155/2011/438056
- Rupina W, Trianto HF, & Fitriyaningrum I. Efek salep ekstrak etanol 70% daun karamunting terhadap re-epitelisasi luka insisi kulit tikus wistar. *eJournal Kedokteran Indonesia*. 2016; 4(1): 26-30. DOI: 10.23886/ejki.4.5905.26-30
- Arwiyah M. Gambaran Histopatologis Penyembuhan Luka Bakar menggunakan Daun Kedondong (*Spondias dulcis* F.) dan Minyak Kelapa pada Tikus Putih (*Rattus Novergicus*). Banda Aceh: Fakultas Kedokteran, 2013. Print
- Jodynis-Liebert J & Kujawska M. Biphasic Dose-Response Induced by Phytochemicals: Experimental Evidence. *Journal of Clinical Medicine*. 2020; 9(3):718. <https://doi.org/10.3390/jcm9030718>
- Anderson JJB, Ambrose WW, Garner SC. Biphasic Effects of Genistein on Bone Tissue in the Ovariectomized, Lactating Rat Model. *Proceedings of the Society for Experimental Biology and Medicine*. 1998;217(3):345-350. doi: 10.3181/00379727-217-44243
- Jenie R., Amalina N., Ilmawati G., Utomo R., Ikawati M., Khumaira A., Kato J. & Meiyanto E. (2019). Cell Cycle Modulation of CHO-K1 Cells Under Genistein Treatment Correlates with Cells Senescence, Apoptosis and ROS Level but in a Dose-Dependent Manner. *Advanced Pharmaceutical Bulletin*. 9. 453-461. 10.15171/app.2019.054.
- Hosseini SN, Karimian A, Mousavinasab SN, Rahmanpour HR, Yamini M, Zahmatkesh SH. Xenoderm versus 1% silver sulfadiazine in partial-thickness burns. *Asian Journal of Surgery*. 2009; 32(4): 234-239. DOI: 10.106/S1015-9584(09)60-400-0.

34. Arslan K, Karahan O, Okuş A, Unlü Y, Eryılmaz MA, Ay S, & Sevinç B. Comparison of topical zinc oxide and silver sulfadiazine in burn wounds: an experimental study. *Ulus Travma Acil Cerrahi Derg.* 2012 Sep;18(5):376-83. doi: 10.5505/tjtes.2012.45381.
35. Ashkani-Esfahani S, Imanieh MH, Khoshneviszadeh M, Meshksar A, Noorafshan A, Geramizadeh B, Ebrahimi S, Handjani F, & Tanideh N. The healing effect of *Arnebia euchroma* in second degree burn wounds in rat as an animal model. *Iran Red Crescent Med J.* 2012 Feb;14(2):70-4.